

# Chronic Rhinitis in Dogs

## Internal Medicine Service



**Michigan Veterinary  
Specialists<sup>sm</sup>**

www.michvet.com

We Can Help

### Available Services

- 24/7 Emergency & Critical Care
- Cardiology
- Computed Tomography
- Dermatology & Allergy
- Internal Medicine
- Interventional Radiology
- MRI
- Neurology
- Neurosurgery
- Oncology
- Oncologic Surgery
- Ophthalmology
- Orthopedic Surgery
- Radiology & Fluoroscopy
- Radiation Therapy
- Soft Tissue Surgery
- Ultrasound

### Locations

#### **Auburn Hills**

3412 E. Walton Blvd.  
(West of Squirrel Rd.)  
(248) 371-3713

#### **Grand Rapids**

1425 Michigan St. NE  
(East of Fuller Rd.)  
(616) 284-5300

#### **Southfield**

29080 Inkster Rd.  
(North of 12 Mile Rd.)  
(248) 354-6660

Chronic nasal disease is an infrequent problem in dogs. However, when present, it commonly becomes a frustrating problem to properly diagnose, and in certain situations to clinically manage. Attempts to achieve an early diagnosis should be made. Symptomatic therapy will unnecessarily delay diagnosis and may lead to situations where treatment becomes exceedingly difficult, or essentially impossible. This is especially important in dogs with fungal rhinitis or nasal neoplasia, where early diagnosis will improve response to therapy.

## Clinical Signs of Nasal Disease

Sneezing and nasal discharge are usually associated with diseases of the nose, paranasal sinuses, and nasopharynx. Sneezing frequently precedes the onset of notable nasal discharge. Dogs having nasal foreign bodies, a peracute onset of explosive sneezing is often seen initially. The frequency and intensity of sneezing is quite variable with most diseases of the nasal cavity. Regardless of the cause for the nasal disease, the severity and frequency of sneezing often diminishes over time as nasal discharge worsens in severity and may change in character. Consequently, dogs with chronic rhinitis are frequently presented with chronic nasal discharge rather than persistent sneezing.

Expiratory (forward) sneezing is typically associated with sinus or intranasal disease. Reverse or inspiratory sneezing (aspiration reflex) is a normal response to mechanical irritation of the dorsal nasopharyngeal mucosa. The presence of persistent reverse sneezing is usually correlated with caudal nasal, nasopharyngeal, or sinus diseases.

Some dogs may have no anterior nasal discharge, and the only indication for primary nasal disease may be the development of obstructive nasal breathing. Obstructive nasal breathing is often first observed while the dog is nasal breathing (i.e., sleeping or resting) and not panting or open mouth breathing. Recurrent pacing or profound restlessness may be seen in some dogs with severe obstructive disease while attempting to rest or sleep due to inability to breathe through the nose.

## Causes for Chronic Nasal Disease in Dogs

Many of the various causes for chronic nasal disease in dogs follow. The principle diseases of the sinonasal cavity associated with chronic nasal disease in dogs are sinonasal neoplasia, idiopathic lymphoplasmacytic (hypersensitivity) rhinitis, and fungal rhinitis.

Nasal discharge is not limited to just diseases of the nose, but may occur with systemic (extranasal) disorders. Very often extranasal disorders have systemic signs (e.g. depression, pyrexia, hemorrhage) with a history of acute onset of nasal signs. Primary nasal disorders, other than nasal foreign bodies, typically have a more chronic duration. Key extranasal disorders that may present with nasal discharge include coagulopathies, vasculitis, hypertension, hyperviscosity syndrome, and pneumonia.

The character and type of nasal discharge may be helpful in developing a list of potential causes, but is not characteristic for specific diseases. Unilateral (one-sided) discharge is often associated with neoplasia, fungal and foreign body rhinitis, and dental disease. Bilateral discharge is typical of systemic disorders, neoplasia, fungal rhinitis, idiopathic lymphoplasmacytic rhinitis, and allergic rhinitis. However, it also is possible for systemic disorders and idiopathic lymphoplasmacytic rhinitis to present with only unilateral nasal discharge. Serous nasal discharge may be seen initially with a variety of nasal disease, but often becomes mucopurulent as disease progresses and secondary bacterial colonization occurs.

Mucopurulent nasal discharge is most common and results from bacterial colonization or bacterial infection *secondary* to an underlying disorder that has damaged the nasal mucosa (inner lining of the nose). Primary bacterial infection is an exceedingly rare cause of chronic rhinitis in dogs. Mucopurulent and serous discharges may be blood-tinged as a result of mucosal erosion. Epistaxis (bleeding from the nose) usually results from an underlying nasal disorder initiating erosion of blood vessels, but also may be seen with systemic disorders such as coagulopathies, hypertension, vasculitis, or hyperviscosity syndrome.

# Chronic Rhinitis in Dogs Continued...

## Primary nasal and paranasal sinus disorders causing nasal discharge

Viral infection	Neoplasia
Canine distemper	Foreign body
Bacterial rhinitis	Dental disease
<i>Bordetella bronchiseptica</i>	Oronasal fistula
<i>Pasteurella multocida</i> (?)	Palatine defects
Fungal rhinitis	Trauma
<i>Aspergillus fumigatus</i>	Allergic rhinitis
<i>Penicillium spp</i>	Hyperplastic rhinitis (Irish wolfhounds)
<i>Rhinosporidium seeberi</i>	Idiopathic granulomatous rhinitis
<i>Cryptococcus neoformans</i>	IgA immunodeficiency
Nasal parasites	Ciliary dyskinesia
<i>Pneumonyssus caninum</i>	Nasopharyngeal turbinates
<i>Eucoleus [Capillaria] boehmi</i>	Nasopharyngeal stenosis
Idiopathic lymphoplasmacytic (hypersensitivity) rhinitis	

## Systemic or extranasal disorders associated with nasal discharge

Environmental agents (dusts, smoke)	Coagulopathies
Cricopharyngeal disease	Thrombocytopenia
Esophageal stricture	Vasculitis
Oropharyngeal diseases	Hyperviscosity syndrome
Megaesophagus	Polycythemia
Pneumonia	Hypertension
Vomiting	

## Diagnosis of Chronic Nasal Disease in Dogs

### Initial evaluation

Clinical history and physical examination findings generally offer an indication for primary nasal disease as opposed to systemic or extranasal disease. Routine laboratory tests (complete blood count, serum chemistries, and urinalysis), coagulation profile, blood pressure and thoracic radiographs are important to rule out most of the systemic or extranasal causes for nasal discharge. Cytologic evaluation of nasal discharge is rarely helpful other than possibly for identification of *Eucoleus [Capillaria] boehmi* parasitic ova.

Bacterial or fungal cultures of nasal discharge are not recommended as they are nonspecific and frequently simply represent resident bacteria and fungi within the nose. Serologic tests for aspergillosis of marginal value because many dogs with active fungal rhinitis will have negative results and dogs with nasal neoplasia may have positive results. Empirical antimicrobial treatment is not advised and merely delays definitive diagnosis unless *Bordetella bronchiseptica* or *Pasteurella multocida* rhinitis (both very rare), or pneumonia is present. Mucopurulent nasal discharge is next to always a result of secondary bacterial colonization due to an underlying primary nasal disease.



**Michigan Veterinary  
Specialists<sub>sm</sub>**

[www.michvet.com](http://www.michvet.com)

# Chronic Rhinitis in Dogs Continued...

## Diagnosis of Chronic Nasal Disease in Dogs (*continued*)

### *Initial evaluation (continued)*

Clinical history and physical examination findings generally offer an indication for primary nasal disease as opposed to systemic or extranasal disease. Routine laboratory tests (complete blood count, serum chemistries, and urinalysis), coagulation profile, blood pressure and thoracic radiographs are important to rule out most of the systemic or extranasal causes for nasal discharge. Cytologic evaluation of nasal discharge is rarely helpful other than possibly for identification of *Eucoleus [Capillaria] boehmi* parasitic ova.

Bacterial or fungal cultures of nasal discharge are not recommended as they are nonspecific and frequently simply represent resident bacteria and fungi within the nose. Serologic tests for aspergillosis of marginal value because many dogs with active fungal rhinitis will have negative results and dogs with nasal neoplasia may have positive results. Empirical antimicrobial treatment is not advised and merely delays definitive diagnosis unless *Bordetella bronchiseptica* or *Pasteurella multocida* rhinitis (both very rare), or pneumonia is present. Mucopurulent nasal discharge is next to always a result of secondary bacterial colonization due to an underlying primary nasal disease.

### *Radiography*

All diagnostic imaging studies require that the patient be under general anesthesia. Imaging studies are essential in most dogs with chronic rhinitis to help achieve a diagnosis. It is critical that imaging studies are completed prior to rhinoscopy or collection of intranasal samples so that secondary hemorrhage does not obscure subtle lesions or affect the quality of diagnostic images. If dental disease is suspected, dental films may be recommended to evaluate the questionable teeth and surrounding structures. Radiographic images of the nose and sinuses may provide some insight but often do not reveal a specific cause for the nasal disease. Due to the complexity of the nose and overlying bony structures, conventional radiography rarely offers the detailed information required to determine an accurate cause for chronic nasal disease in dogs. Radiographs also suffer from lack of sufficient resolution to identify or localize early nasal disease.

### *Nasal Computed Tomography*

Computed tomography (CT) is the diagnostic imaging study of choice for evaluation of the nasal cavity, paranasal sinuses, tympanic bulla, periorbital region, and skull. Nasal CT is superior to conventional radiography for detecting subtle changes within the nasal cavity, determining the extent and severity of disease processes, and differentiation of infectious or inflammatory disease from nasal neoplasia. Unlike CT, conventional radiographs have poor sensitivity for differentiating inflammatory rhinitis from neoplasia and fungal rhinitis. Image acquisition time (time spent under anesthesia) for nasal CT is also considerably less than that for routine nasal and skull radiographs. Rhinoscopy is not recommended in lieu of nasal CT in that rhinoscopy alone frequently affords limited information about the extent of the disease because of the internal complexity of the nasal cavity. The presence of mucopurulent or hemorrhagic nasal discharge also prevents satisfactory visualization within the nasal cavity. The nasal sinuses also cannot be routinely visualized with rhinoscopy.

Nasal CT is a rapid imaging modality that utilizes x-rays and complex computers to construct cross-sectional images of the nose, paranasal sinuses, and skull. The ability to obtain cross-sectional images allows for evaluation of internal structures and anatomical relationships that cannot be seen on conventional radiographs. Because x-rays are used to construct the tomographic images, the interpretation of computed tomography studies is comparable to basic radiographic principles. Computed axial tomography images are made by rotating an x-ray tube head around the patient in the area of interest. When image slices are collected in an axial fashion, the computed tomography table supporting the patient is held stationary during the time required to complete one revolution of the x-ray tube head. The computed tomography table then advances the patient a predetermined slice interval through the gantry and the next acquisition takes place.

The images acquired by CT provide a thorough assessment of the nasal cavities and paranasal sinuses, extent of disease present and superior insight to the nature of the disease. Nasal CT studies often can differentiate neoplastic nasal disease from fungal rhinitis and inflammatory rhinitis. Contrast-enhanced CT images are occasionally used and may be useful to distinguish between vascularized soft tissues versus mucous accumulation. Because nasal CT will clearly demonstrate the location and extent of nasal disease, it is often used to help guide post-imaging rhinoscopic and biopsy procedures.



**Michigan Veterinary  
Specialists<sub>sm</sub>**

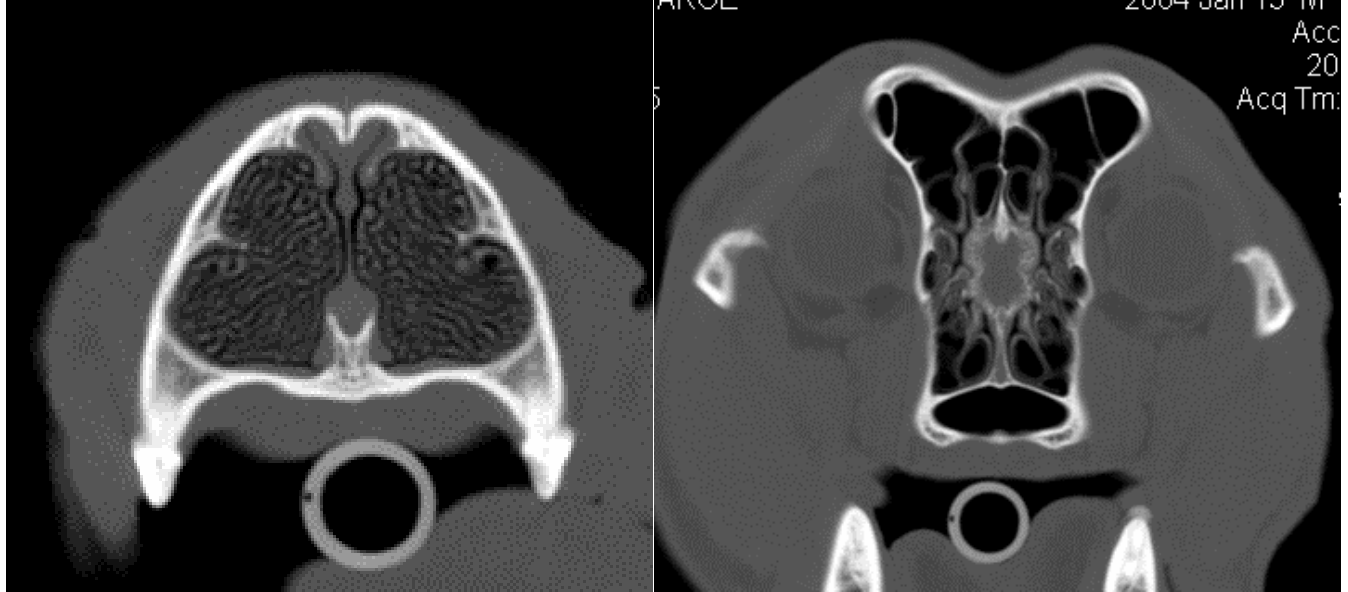
[www.michvet.com](http://www.michvet.com)

# Chronic Rhinitis in Dogs Continued...

## Diagnosis of Chronic Nasal Disease in Dogs (*continued*)

### *Nasal Computed Tomography (continued)*

Selected computed tomography (CT) images of a normal dog nose



(Images courtesy of Ned F. Kuehn, DVM, MS, DACVIM - Michigan Veterinary Specialists)

### **Rhinoscopy**

Rhinoscopy should be performed only after all imaging studies are completed with the patient remaining under anesthesia. This is so that endoscopy-induced hemorrhage does not obscure the imaging studies. Retroflex nasopharyngoscopy is performed by turning a small flexible scope 180 degrees around the caudal margin of the soft palate for visualization and evaluation of the caudal nares, dorsal soft palate, and nasopharynx. Tumors or foreign bodies lodged within the caudal nares or within the nasopharynx occasionally cause chronic rhinitis in dogs and are readily visualized with this procedure.

Anterior rhinoscopy is performed by direct passage of a scope through the rostral nares, which allows for direct visualization of structures within the nasal cavity. Evaluation of the nasal cavity is often limited by the size of the scope in relation to the size of the nasal cavity, lesion location, and impeded visualization of intranasal structures by mucous or hemorrhage. The convoluted nature of the nasal passages will not allow for evaluation of the entire nasal cavity, so foreign bodies and neoplastic masses may be overlooked. Although rhinoscopy has utility in the diagnosis of chronic nasal disease, the various limitations outlined above severely limit its use as a sole or preferred diagnostic test procedure. When available, nasal computed tomography is a vastly superior method for evaluation of the entire nasal cavity.

During rhinoscopy, the nasal mucosa is evaluated for color, vascularity, friability, edema, and presence of parasites or fungal plaques. The nasal passages should be evaluated for obstruction by tissue masses, foreign bodies, or secretions. A loss of normal nasal turbinates would indicate the presence of a destructive rhinitis secondary to fungal infection or severe idiopathic lymphoplasmacytic rhinitis. Rhinoscopy is especially helpful to aid in the diagnosis of fungal rhinitis and rostrally positioned nasal foreign bodies. Fungal rhinitis is associated with widespread turbinate destruction. Rhinoscopy reveals a cavernous nasal cavity, frequently with white to grey fungal plaques scattered within the surface of the nasal mucosa.



**Michigan Veterinary  
Specialists<sub>sm</sub>**

[www.michvet.com](http://www.michvet.com)

# Chronic Rhinitis in Dogs Continued...

## Diagnosis of Chronic Nasal Disease in Dogs (*continued*)

### *Nasal Biopsy*

Procurement of nasal specimens and biopsies of nasal tissue should only be performed after all imaging studies are completed with the patient remaining under anesthesia. Cytology of nasal secretions is rarely useful. Brush cytology from masses or fungal plaques may be useful in establishing a diagnosis. Stained direct smears of nasal tissue specimens also can be useful for identifying fungal organisms. Tissue from lesions visualized during rhinoscopy may be obtained either by direct biopsy with forceps passed either adjacent to or through the endoscope. Rhinoscopic-directed biopsies of masses may be limited by the small size of tissue samples obtained and confounded by inflammation surrounding the mass. Lymphoplasmacytic inflammation often is concurrent with intranasal neoplasia, whereas idiopathic lymphoplasmacytic rhinitis is not associated with mass lesions in the nose. It is often preferable to use nasal CT images to provide a guide for procurement of biopsy samples. Specialized biopsy forceps are advanced to the site of disease as identified from CT images with multiple biopsies being obtained. Nasal lavage may be required to dislodge foreign material identified or suspected to be present within the nose.

Nasal tissue samples from dogs are not routinely submitted for bacterial or fungal culture unless osteomyelitis is present. Nasal fungal and bacterial tissue cultures must be interpreted cautiously because fungal and bacterial isolates may be a consequence of nasal passage colonization rather than the cause of a given disease process. Primary bacterial rhinitis is exceedingly rare in the dog and bacterial infections are almost invariably secondary to underlying primary nasal disease. A heavy growth of even one or two bacterial isolates may merely be indicative of bacterial colonization; however, pure isolates of *Bordetella bronchiseptica* and possibly *Pasteurella multocida* may be significant if the clinical history is supportive. Dogs with nasal neoplasia or nasal foreign bodies (and occasionally normal dogs) may have positive fungal cultures for *Aspergillus* species. A positive fungal culture should be supported by diagnostic imaging (CT) studies, cytological, rhinoscopic, or histological evidence of infection. If tissue cultures are submitted, they must be carefully interpreted in light of histopathologic and other diagnostic information.

## COMMON CAUSES OF CHRONIC RHINITIS IN DOGS

The most common causes for chronic rhinitis in dogs are neoplasia, idiopathic chronic (lymphoplasmacytic) rhinitis, and fungal rhinitis. Parasitic rhinitis (nasal mites or nematodes) is uncommon. Allergic rhinitis is often mild, and clinical signs may not be appreciated. Bacterial rhinitis is rare in dogs and largely due to infection with *Bordetella bronchiseptica*. Nasal foreign bodies and dental disease may be occasional causes for chronic nasal discharge.

### Fungal Rhinitis

Fungal rhinitis is a relatively common cause of chronic rhinitis in the dog within various geographic regions throughout North America. *Aspergillus fumigatus* is the most common cause of fungal rhinitis in dogs, but occasionally *Penicillium* species and *Rhinosporidium seeberi* and very rarely *Cryptococcus neoformans* may cause disease. *Rhinosporidium seeberi* often presents as a granulomatous mass within the rostral nasal cavity. Cytology of tissue from these granulomatous masses is often diagnostic. Treatment for rhinosporidiosis is best accomplished by aggressive surgical resection of the granulomatous mass.

Nasal aspergillosis is most commonly seen in young to middle-aged dolichocephalic dogs with German shepherd and Rottweiler breeds reported to be predisposed. Affected dogs present with copious unilateral or bilateral mucopurulent nasal discharge. Sneezing is common and may be accompanied by mild to severe epistaxis. Facial pain and depigmentation and ulceration of the nasal planum may be present. In contrast to nasal neoplasia, facial distortion is unusual in all but advanced cases of fungal rhinitis.

Nasal CT along with rhinoscopic visualization of the nasal cavity is noteworthy for the presence of dramatic turbinate loss within the nasal cavity. Sinus involvement may be present. Invasion through the maxillary or palatine bones with extension into surrounding soft tissue structures is occasionally seen. Nasal CT scan is preferred over radiographs so that the integrity of the cribriform plate prior may be evaluated prior to local antifungal therapy.



**Michigan Veterinary  
Specialists<sub>sm</sub>**

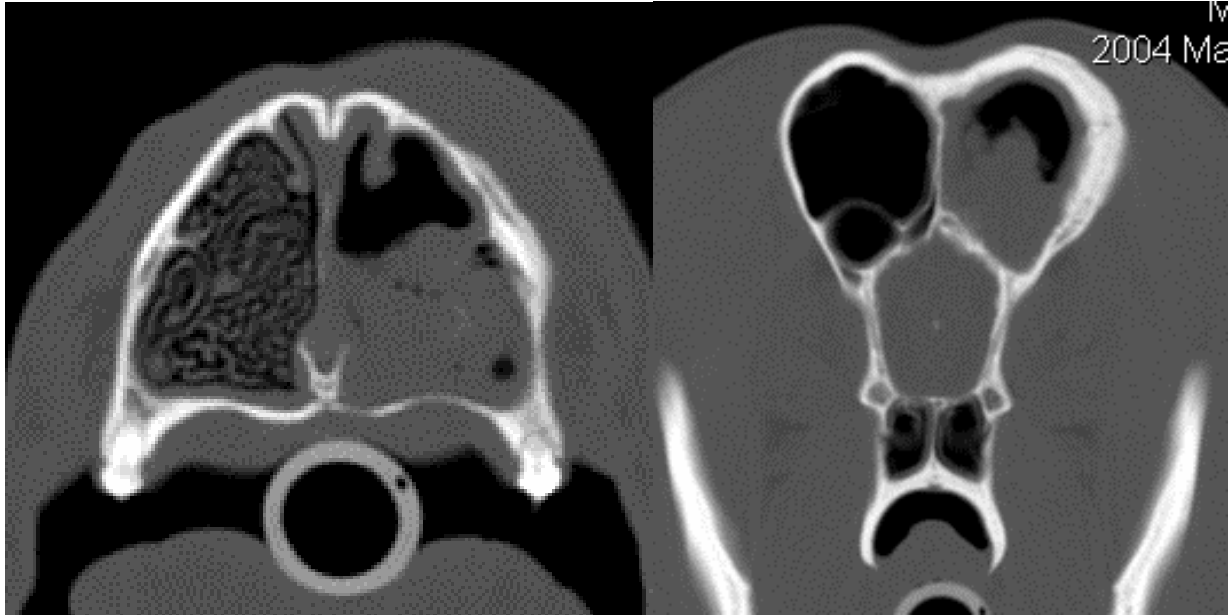
[www.michvet.com](http://www.michvet.com)

# Chronic Rhinitis in Dogs Continued...

## COMMON CASUSES OF CHRONIC RHINITIS IN DOGS

### Fungal Rhinitis (*continued*)

Selected computed tomography (CT) images from a dog with fungal infection of the nose and frontal sinus



(Images courtesy of Ned F. Kuehn, DVM, MS, DACVIM - Michigan Veterinary Specialists)

The CT image on the left shows near total loss of nasal turbinates and scattered soft tissue attenuating densities within the right nasal cavity. This finding is characteristic of fungal rhinitis. The CT image on the right shows thickening of the bone of right frontal sinus with mucosal edema. The irregularly marginated soft tissue attenuating density within the left frontal sinus is site of fungal infection.

Diagnosis of nasal aspergillosis is confirmed by visualization of fungal plaques on nasal mucosa and demonstration of branching septate hyphae on cytologic or histologic samples from affected regions within the nose. There is high accuracy of cytology samples in the diagnosis of nasal aspergillosis or penicilliosis when collection is done under direct endoscopic visualization; whereas, there is poor value of samples collected by blind swabs or preparations from samples of nasal discharge. Serologic tests positive for aspergillosis also support the diagnosis although negative results may occur even with extensive disease. Cultures of nasal discharge may be misleading in that 30-40% of cultures from normal dogs and those with nasal neoplasia can yield *Aspergillus* or *Penicillium* species. Despite properly obtained samples there are some cases that fail to demonstrate fungal organisms. Repeated sampling or a trial of antifungal drugs may well be indicated in dogs with a high index of suspicion for nasal aspergillosis, especially if nasal CT findings are consistent with fungal rhinitis.

The prognosis for treatment of nasal aspergillosis is fair to good, but relapses are possible necessitating re-treatment. Treatment of nasal aspergillosis has classically been approached with topical infusion of either clotrimazole or enilconazole, providing the cribriform plate is intact. Topical therapy is more effective than orally administered antifungal agents. Debridement and removal of diseased turbinate structures through the rostral nares prior to topical therapy will greatly improve response to treatment. Topical therapy with either drug alone is not effective in dogs in which the organism has invaded soft tissue structures adjacent to the nose. In these cases, topical therapy is recommended to be combined with systemic antifungal agents. Exploratory rhinotomy and turbinectomy prior to topical or oral antifungal therapy is often detrimental and not recommended.



**Michigan Veterinary  
Specialists<sub>sm</sub>**

[www.michvet.com](http://www.michvet.com)

# Chronic Rhinitis in Dogs Continued...

## COMMON CAUSES OF CHRONIC RHINITIS IN DOGS

### Fungal Rhinitis (*continued*)

The topical application of enilconazole through surgically placed catheters into the frontal sinuses and nasal chambers has a success rate up to 90%. This procedure is quite distressing to most patients, however. Catheters are implanted surgically into both nasal chambers and frontal sinuses via trephine holes in the sinuses. Enilconazole is flushed through the catheters twice daily at a dosage of 10 mg/kg for a total of 7-10 days. Complications include premature removal of the catheters, subcutaneous emphysema, inappetence, and ptyalism. Some patients may become aggressive and intolerant of the procedure necessitating premature abandonment of therapy. Because of these serious and frequent side-effects, topical therapy with clotrimazole is the treatment of choice.

Clotrimazole is applied as a soak with the solution maintained in the nasal cavities for 1 hour with the patient under anesthesia. A total volume of 60 ml of a 1% solution of clotrimazole is slowly infused through catheters placed into the right and left nares. A nasopharyngeal Foley catheter and sponges placed in the caudal pharyngeal region are positioned prior to the procedure to minimize leakage of the infusate caudally. The head is rotated every 15 minutes to ensure contact with all nasal surfaces. Up to 90% of patients may be cured with a single procedure, although some dogs will require a second procedure 3 weeks later. Side effects of clotrimazole therapy include severe pharyngitis and pharyngeal edema.

Recently another approach with excellent success rate, shorter treatment time, and low patient morbidity has been reported using a combination of clotrimazole irrigation and depot therapy. Frontal sinus trephination is followed by a short, five-minute flushing of 1% topical clotrimazole solution followed by a 1% clotrimazole cream instilled as a depot agent into the frontal sinuses. The dog is positioned in sternal recumbency with the pharynx packed with cotton gauze to prevent aspiration of fluid debris and the head is tilted downwards to allow fluid from the nasal sinuses to drain rostrally. The frontal bone is trephined to permit passage of a catheter into each sinus. The sinuses are first irrigated with 500-1000 ml of warm saline over 5-10 minutes to establish appropriate catheter placement and patency of the nasofrontal ostium. The sinuses are then irrigated with 1% clotrimazole solution. For dogs weighing more than 10 kg, a total of 1 g of clotrimazole solution is used (50 ml per side) and for dogs weighing less than 10 kg, a total of 500 mg is used (25 ml per side). Clotrimazole 1% cream is then introduced into the frontal sinuses. For dogs weight more than 10 kg, a total of 40 g (20 g per side) is used and for dogs weighing less than 10 kg a total of 20 g (10 g per side) is used. The catheters are then removed, the skin incisions are closed, and excess fluid is allowed to drain from the sinuses before the pharyngeal gauze is removed. With this treatment protocol, 86% of dogs with nasal aspergillosis or penicilliosis established a cure from infection, although a second treatment 3 weeks later is often required.

Oral antifungal agents have relatively poor efficacy against *Aspergillus spp.* infection, but are recommended if the cribriform plate is penetrated. Oral antifungal agents are used in combination with topical agents if invasion of local bone and soft tissue structures is present. The newer azole derivatives have the best results. Side effects of the azole antifungal agents include anorexia, vomiting, lethargy, elevated BUN, skin ulcerations, fever, and hepatotoxicity. Itraconazole (Sporanox®, Janssen) is recommended due to its low toxicity. Itraconazole given for 3-6 months may cure up to 60-70% of dogs with aspergillosis, although some studies have shown marginal effects of this drug on this disease. Terbinafine (Lamisil®, Novartis) is another option and well tolerated. Terbinafine appears to have similar efficacy to itraconazole when given for 3-6 months. Fluconazole (Diflucan®, Pfizer) is an additional alternative with a cure rate up to 60% when given for 3-6 months. Voriconazole (Vfend®, Pfizer) is a new generation broad-spectrum antifungal agent that shows activity against a wide range of yeasts and filamentous fungi. Voriconazole demonstrates both fungicidal and fungistatic activities *in vitro* against *Aspergillus spp.* superior to that of fluconazole.

### Idiopathic Lymphoplasmacytic (Chronic) Rhinitis

Idiopathic lymphoplasmacytic rhinitis is a relatively common cause of chronic nasal disease in the dog. The definitive etiology of lymphoplasmacytic rhinitis remains undetermined; however, it is likely a stereotyped chronic inflammatory response to multiple precipitating factors. Inhaled aeroallergens and irritants likely play a primary role in development of this disease. Hypersensitivity to native commensal fungal organisms within the nose also may play a role in some patients. Typically middle-aged to older dolichocephalic and mesaticephalic large breed dogs and Dachshunds are affected.



**Michigan Veterinary  
Specialists<sub>sm</sub>**

[www.michvet.com](http://www.michvet.com)

# Chronic Rhinitis in Dogs Continued...

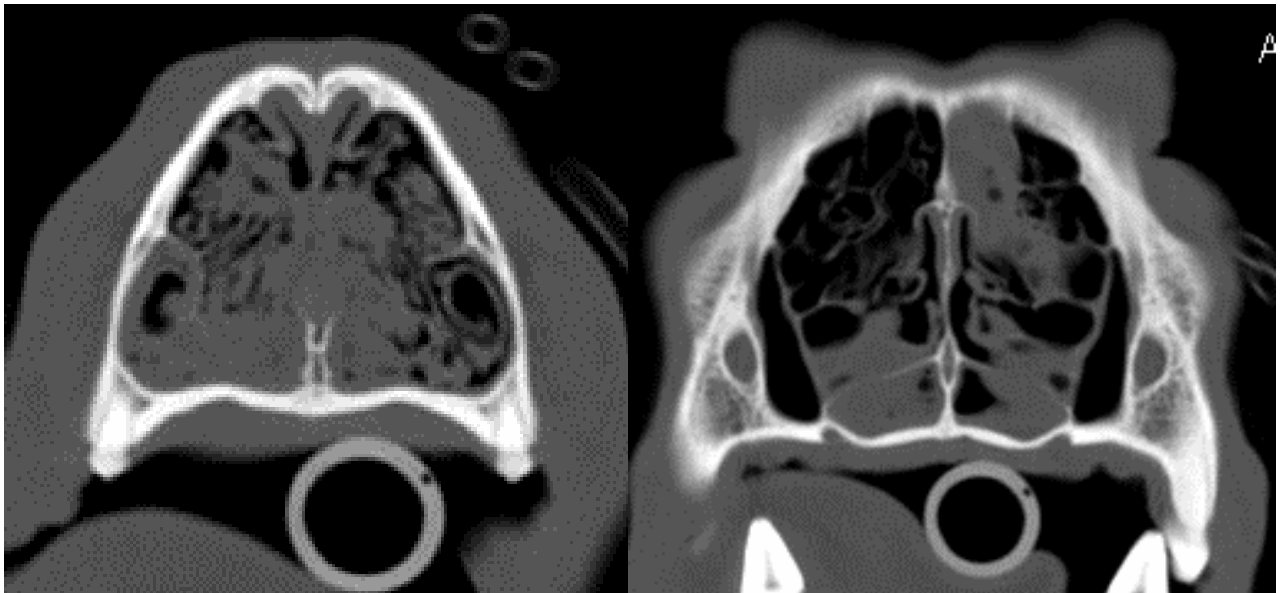
## COMMON CASUSES OF CHRONIC RHINITIS IN DOGS

### Idiopathic Lymphoplasmacytic (Chronic) Rhinitis (*continued*)

Chronic unilateral to bilateral mucoid to mucopurulent nasal discharge is often present, although some dogs may have mucohemorrhagic discharge or epistaxis. Obstruction to airflow through the nose may result from excessive mucous within nasal passages and turbinate mucosal edema. Lymphoplasmacytic inflammation may be present with nasal neoplasia, fungal rhinitis or foreign body rhinitis; therefore, it is imperative that these diseases be thoroughly excluded before a diagnosis of idiopathic lymphoplasmacytic (chronic) rhinitis is entertained.

Nasal radiography is not sufficient to differentiate chronic inflammatory rhinitis from neoplasia or fungal rhinitis because similar changes such as turbinate destruction and soft tissue opacification of the nasal passages and frontal sinus may be seen in each of these diseases. Nasal CT is recommended because it greatly enhances the ability to differentiate inflammatory from neoplastic diseases. Nasal CT lesions with idiopathic chronic rhinitis may be completely unremarkable or disclose unilateral or bilateral mild to moderate turbinate destruction with mucous accumulation within air passages and sinuses. Occasionally the turbinate destruction may be severe mimicking that seen with fungal rhinitis. Destruction of the nasal septum, frontal sinuses or cribriform plate, or extension of soft tissue density into the nasopharynx or periorbital region is not expected with idiopathic chronic rhinitis and should prompt investigation into fungal rhinitis or neoplastic disease.

#### Selected computed tomography (CT) images from a dog with idiopathic lymphoplasmacytic rhinitis



(Images courtesy of Ned F. Kuehn, DVM, MS, DACVIM - Michigan Veterinary Specialists)

The CT image on the left shows scattered soft tissue attenuating densities (representing mucous) between nasal turbinates within both sides of the nasal cavity. The CT image on the right is further back within the nose showing similar changes.

The most common rhinoscopic abnormalities seen are unilateral or bilateral erythema or hyperemia and edema of the nasal mucosa with the presence of mucopus with air passages. Turbinate atrophy or loss is occasionally appreciated. Nasal samples for microbial culture are not informative and not recommended. Histologic changes include mild to severe lymphoplasmacytic inflammation with occasional infiltration of neutrophils or eosinophils. Turbinate remodeling or destruction may be absent or vary from mild to severe. The severity of histologic changes may show discordance between the right and left sides of the nasal cavity.



**Michigan Veterinary  
Specialists<sub>sm</sub>**

[www.michvet.com](http://www.michvet.com)

# Chronic Rhinitis in Dogs Continued...

## COMMON CAUSES OF CHRONIC RHINITIS IN DOGS

### Idiopathic Lymphoplasmacytic (Chronic) Rhinitis (*continued*)

***Treatment for idiopathic lymphoplasmacytic rhinitis is extremely frustrating with cure rarely achieved.*** Although this is not a life-threatening disease, owners of dogs so affected are often distraught by their pets nasal obstruction or the need to frequently clean up nasal discharge or nasal hemorrhage within the house.

Allergen avoidance is rarely helpful; however, avoidance of secondhand smoke can substantially reduce signs in some dogs. Despite earlier reports in the literature, systemic corticosteroids are seldom effective in controlling clinical signs, and actually may worsen clinical signs. The use of oral glucocorticoid medications should probably be avoided. Topical glucocorticoid therapy with nasal steroid drops or aerosolized steroids administered using metered dose inhalers attached to a spacer and tightly fitting facemask has been shown anecdotal promise in some dogs with chronic rhinitis.

Antihistamine medications are rarely effective, but they occasionally slightly reduce the severity of nasal discharge. Long-term administration of antibiotics having immunomodulatory effects combined with nonsteroidal antiinflammatory agents can be helpful in some dogs. Doxycycline or azithromycin in combination with piroxicam is recommended. If distinct clinical improvement is observed within 2 weeks, daily piroxicam therapy is continued but the frequency of administration of doxycycline is reduced to once daily or azithromycin reduced to twice weekly. Therapy will likely be required for a minimum of 6 months if not indefinitely.

We are currently investigating the use of oral itraconazole therapy in those dogs refractory to other therapeutic modalities out of reasoning that chronic fungal hypersensitivity to ubiquitous fungi may play a role in this disease. Chronic rhinosinusitis in humans is an inflammatory disease with numerous predisposing factors, including genetics, pollution, anatomic abnormalities, bacteria, and fungi or molds. Hypersensitivity to ubiquitous fungi is currently thought to play a role in some people with chronic rhinosinusitis. Immune sensitization to ubiquitous fungi with subsequent production of various cytokines has been proposed as initiating and later perpetuating factors for chronic rhinosinusitis in humans. Topical antifungal therapy has been shown to benefit some human patients with chronic rhinosinusitis, but not others. Nasal biopsies from dogs with lymphoplasmacytic rhinitis have been reported to display an elevated transcription of fungal genes as compared to dogs with nasal neoplasia using PCR techniques. Whether hypersensitivity to ubiquitous commensal nasal fungal organisms is involved or molecular techniques are detecting entrapment of fungal organisms is unclear. Preliminary experience with the administration of itraconazole 5 mg/kg q12h, PO for a minimum of 3-6 months has shown a dramatic beneficial improvement of clinical signs in some dogs with this disease.

### Nasal Neoplasia and Nasal Polyps

Nasal neoplasia is an important cause of chronic nasal disease primarily in older dolichocephalic and mesaticephalic dogs. Nasal neoplasia accounts for approximately one third of all dogs with chronic nasal disease. Tumors of epithelial origin account for approximately two thirds of canine nasal neoplasms. Nasal tumors are nearly always malignant and primarily arise within the nasal cavity, although they occasionally may arise in the paranasal sinuses. Nasal tumors are primarily locally invasive with local to widespread destruction of nasal turbinates seen initially and invasion of septal, cribriform, or facial bones later in the course of disease. Metastasis to regional lymph nodes or lung may occur, but this is rare and generally occurring in the very late stage of disease.

Clinical signs are primarily related to obstruction of air flow through the nasal cavities, mucopurulent nasal discharge, epistaxis, sneezing, and reverse sneeze. Facial deformity or swelling, exophthalmia, or neurological signs may be seen as a result of tumor destruction of facial bones or cribriform plate. Facial pain and head shyness is rarely seen (unlike that with fungal rhinitis). In some patients, initial clinical signs may be very subtle with unexplained onset of snoring and occasional reverse sneeze reported.

For dogs presenting primarily for epistaxis, additional laboratory studies may be recommended in order to rule out coagulation disorders, hypertension, and hyperviscosity syndromes as possible causes for epistaxis prior to nasal diagnostic imaging studies and nasal biopsy. Nasal radiographs are frequently limited in their ability to distinguish subtle lesions or changes seen with nasal tumors that overlap with chronic and fungal rhinitis. Nasal CT is a vastly superior imaging modality for differentiating neoplastic from nonneoplastic disease and detection of bone destruction and neoplastic extension into surrounding structures. Nasal CT also is needed for staging, to delineate tumor boundaries, and to plan for radiation therapy.



**Michigan Veterinary  
Specialists<sup>sm</sup>**

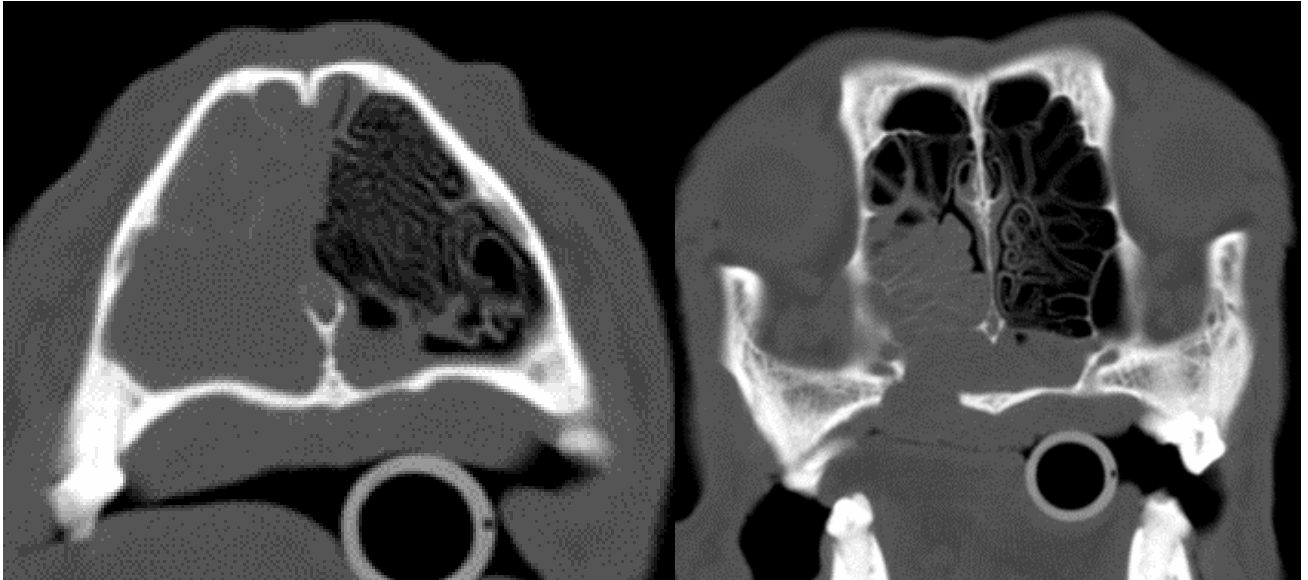
[www.michvet.com](http://www.michvet.com)

# Chronic Rhinitis in Dogs Continued...

## COMMON CASUSES OF CHRONIC RHINITIS IN DOGS

### Nasal Neoplasia and Nasal Polyps (*continued*)

Selected computed tomography (CT) images from a dog with nasal carcinoma



(Images courtesy of Ned F. Kuehn, DVM, MS, DACVIM - Michigan Veterinary Specialists)

The CT image on the left shows a uniform soft tissue attenuating density (representing cancer) within the left nasal cavity. There is destruction of the nasal septum with extension into the right nasal cavity. The CT image on the right is further back within the nose. There is extension of the cancer into the nasopharyngeal meatus and on the left side destruction of the hard palate is present.

Retroflex nasopharyngoscopy is suggested to evaluate the nasopharyngeal region and identification of tumor extension through the caudal nares. Anterior rhinoscopy in dogs with nasal neoplasia may reveal a mass lesion protruding within and occluding nasal air passages. Multiple biopsies of masses should be obtained to increase the likelihood of diagnosis as severe inflammation often surrounds nasal tumors. Frequently nasal tumors cannot be visualized due to hemorrhage or because their origin is in an inaccessible region of the nose. For these reasons, nasal CT studies are critical to facilitate direction and location of the affected region of the nose.

Radiation therapy is the treatment of choice for most nasal tumors. Thoracic radiographs are recommended when nasal neoplasia is identified prior to radiation therapy to rule out metastatic lung disease. Surgery alone is ineffective with survival times similar to that observed in untreated dogs. Depending on the mode of radiation therapy available, approximate median survival times are between 16.5-23 months and approximate 1 year survival rates are between 54-60% in dogs with nasal neoplasia. Exenteration of the nasal cavity following accelerated radiotherapy significantly prolongs survival time in dogs with intranasal neoplasia over radiotherapy alone. There is limited information on the response of nasal tumors to chemotherapy alone. The median survival in a very small group of dogs with nasal adenocarcinoma given cisplatin alone was 20 weeks, which is comparable to no treatment. However, cisplatin is occasionally used as a radiation sensitizer in radiotherapy protocols.

Polyps within the nasal cavity are very rare in dogs. These are usually unilateral and rhinotomy is required for removal of the polypous tissue and surrounding conchae. Recurrence 1-2 years later is possible. To date, in all dogs we have seen with an initial diagnosis of a polyp, careful review of nasal CT has demonstrated localized turbinate destruction and the subsequent histologic diagnosis following surgical resection of the polypous tissue has been low-grade fibrosarcoma associated with moderate to severe chronic inflammation.



**Michigan Veterinary  
Specialists<sup>sm</sup>**

[www.michvet.com](http://www.michvet.com)